

# Super-dose Anti-VEGF (SAVE) Trial: 2.0 mg Intravitreal Ranibizumab for Recalcitrant Neovascular Macular Degeneration—Primary End Point

David M. Brown, MD, Eric Chen, MD, Angeline Mariani, BA, James C. Major, Jr., MD, PhD,  
for the SAVE Study Group

**Purpose:** To determine whether a higher dose of intravitreal ranibizumab could improve the anatomy and best-corrected visual acuity (BCVA) in eyes with neovascular age-related macular degeneration (AMD) with persistent disease activity despite monthly intravitreal anti-vascular endothelial growth factor (VEGF) injections.

**Design:** Phase I to II multicenter, open-label, controlled clinical trial.

**Participants:** Eighty-seven patients with recalcitrant neovascular AMD, defined as having leakage on fundus fluorescein angiography or spectral domain optical coherence tomography (SD-OCT) despite monthly anti-VEGF injections.

**Methods:** Patients were treated with 2.0-mg ranibizumab injections monthly for 3 doses and monitored with Early Treatment Diabetic Retinopathy Study (ETDRS) 4-m refractions, clinical examinations, and SD-OCT.

**Main Outcome Measures:** The mean change in baseline visual acuity (VA), the percentage of patients who experienced a loss or gain of 15 or more letters in ETDRS BCVA, the mean change in central retinal thickness, and the incidence of adverse events.

**Results:** Eighty-seven patients with an average of 24 injections before enrollment and a mean of 10.4 injections in the preceding 12 months had a mean refracted VA of 69.2 ETDRS letters (20/41 Snellen) and a mean central subfield of 422  $\mu\text{m}$  at baseline. Mean VA gain over baseline was +2.5 letters at day 7 ( $n = 82$ ), +3.7 letters at month 1 ( $n = 87$ ), +3.9 letters at month 2 ( $n = 87$ ), and +3.3 letters at month 3 (20/36 Snellen;  $P = 0.001$ ;  $n = 86$ ). Anatomic outcomes showed a mean optical coherence tomography central subfield thickness improvement from baseline of  $-48.4 \mu\text{m}$  at day 7 ( $n = 84$ ),  $-37.5 \mu\text{m}$  at month 1 ( $n = 87$ ),  $-42.4 \mu\text{m}$  at month 2 ( $n = 85$ ), and  $-33.1 \mu\text{m}$  at month 3 ( $P = 0.01$ ;  $n = 86$ ).

**Conclusions:** Intravitreal injections of 2.0 mg ranibizumab led to statistically significant VA gains and anatomic improvement in patients with persistent intraretinal, subretinal, or subretinal pigment epithelial fluid during a previous regimen of chronic monthly 0.5-mg ranibizumab injections.

**Financial Disclosure(s):** The author(s) have no proprietary or commercial interest in any materials discussed in this article. *Ophthalmology* 2013;120:349–354 © 2013 by the American Academy of Ophthalmology.

The standard of care treatment of neovascular age-related macular degeneration (AMD) is based on anti-vascular endothelial growth factor (VEGF) therapies with intravitreal ranibizumab (Lucentis, Genentech, Inc., South San Francisco, CA), bevacizumab (Avastin, Genentech, Inc.), or aflibercept (Eylea, Regeneron, Tarrytown, NY).<sup>1,2</sup> Despite monthly treatment, many patients continue to have persistent intraretinal, subretinal, or subretinal pigment epithelium fluid. The Comparison of Age-Related Treatments Trial (CATT) demonstrated persistent fluid with time domain optical coherence tomography (OCT) in 53.2% and 70.9% of patients treated monthly with standard dose ranibizumab and bevacizumab, respectively.<sup>3</sup> Because there are no other alternatives to treat these patients, there exists a significant unmet need for treatment that has increased potency, longer duration of action, or a complementary mechanism of action to eliminate fluid in these recalcitrant cases.

The pivotal phase III Minimally Classic/Occult Trial of the Anti-VEGF Antibody Ranibizumab in the Treatment of Neovascular Age-Related Macular Degeneration (MARINA) and Anti-VEGF Antibody for the Treatment of Predominantly Classic Choroidal Neovascularization in AMD (ANCHOR) trial seemed to demonstrate a dose-response curve with 0.5 mg ranibizumab being more efficacious in functional and anatomic outcomes compared with 0.3 mg ranibizumab. On the basis of the dose-response findings and unmet medical need, we hypothesize that a higher dose of ranibizumab might improve efficacy, leading to better outcomes for patients who are “incomplete responders” to conventional monthly therapy.

## Materials and Methods

This study was a phase I to II multicenter, open-label, randomized, controlled clinical trial (Food and Drug Administration Investiga-

tional New Drug #106985). After obtaining approval of the study protocol and consent by the Western Institutional Review Board, 90 patients seen at Retina Consultants of Houston were identified, provided with informed consent documents, and enrolled.

### Inclusion/Exclusion Criteria

Inclusion criteria included any neovascular lesion type of AMD receiving at least 9 injections of 0.5 mg/0.05 ml intravitreal ranibizumab (Lucentis, Genentech, Inc.) or 1.25 mg/0.05 ml bevacizumab (Avastin, Genentech, Inc.) in the past 12 months with evidence of persistent exudation on OCT or fundus fluorescein angiography, best-corrected Early Treatment Diabetic Retinopathy Study (ETDRS) visual acuity (VA) between 20/25 and 20/320 (Snellen equivalent),<sup>4</sup> and total area of subretinal hemorrhage and fibrosis comprising less than 50% of the total lesion. Persistent OCT leakage was defined as any of the following: intraretinal cysts, subretinal fluid, or serous pigment epithelial detachment.<sup>5</sup> Exclusion criteria included any history of vitrectomy surgery, previous treatment with verteporfin photodynamic therapy at standard or half fluence, any previous radiation treatment, any previous intravitreal drug delivery aside from ranibizumab or bevacizumab within the past 12 months, subretinal hemorrhage involving the central fovea >1 disc area (2.54 mm<sup>2</sup>), subfoveal atrophy, choroidal neovascular membrane secondary to causes other than AMD, or previous retinal pigment epithelial tear.

### Protocol Visits and Testing Procedures

At all visits, subjects underwent ETDRS refracted best-corrected visual acuity (BCVA) testing at 4 m, Goldman applanation tonometry, slit-lamp examination, and dilated binocular indirect ophthalmoscopy. Fundus photographs, fluorescein angiograms, and autofluorescence imaging of both eyes were taken at baseline and months 6, 12, 18, and 24. Optical coherence tomography of both eyes was performed at every visit using the Stratus OCT (Carl Zeiss Meditec, Inc., Dublin, CA), Heidelberg Spectralis HRA+ OCT (Spectralis; Heidelberg Engineering, Heidelberg, Germany), and Cirrus HD-OCT (Cirrus; Carl Zeiss Meditec, Inc.). We assessed the central retinal thickness with an image-tracked, 49-line, 768-Ascans-per-line Heidelberg Spectralis volume scan, and images were on average scanned 9 times to reduce noise. The OCT segmentations (internal limiting membrane and Bruch's membrane) on the Heidelberg Spectralis were manually corrected (by A.M., D.M.B., and J.C.M.) before computation of change maps and change in central retinal thickness. Qualitative OCT analysis (for intraretinal cysts, subretinal fluid, subretinal pigment epithelium fluid, and outer retinal tubulation) was performed on the basis of the best images from the Heidelberg Spectralis volume scans or the Zeiss Cirrus cube or raster scans. All subjects received 0.5 ml open-label intravitreal injections of 2.0 mg ranibizumab (formulated by Genentech, Inc.) administered every 28 days for 3 months (day 0, month 1, month 2) and were reevaluated at month 3 or 3.5 before rolling into a capped pro re nata (PRN) phase. At baseline, patients were randomized (by coin toss) to receive intermediary PRN treatment visits at monthly (cohort A) or 6-week (cohort B) intervals, with all patients scheduled to receive mandatory quarterly injections during the capped PRN phase. Between months 12 and 24 of the study, patients in cohort B were assessed every month. The PRN treatments were performed for any persistent or recurrent leakage on fluorescein angiogram or evidence of intraretinal cysts, subretinal fluid, or subretinal pigment epithelium fluid on spectral domain (SD) OCT.

### Procedures

Sterile surgical techniques were followed for every injection. Patients self-administered topical antimicrobials (e.g., ofloxacin ophthalmic solution [Ocuflox, Allergan Inc., Irvine, CA], gatifloxacin ophthalmic solution [Zymar, Allergan Inc.], moxifloxacin ophthalmic solution [Vigamox, Alcon Laboratories Inc., Ft. Worth, TX], or trimethoprim-polymyxin B ophthalmic solution [Polytrim, Allergan Inc.]) 4 times daily for 3 days before treatment. Proparacaine-, tetracaine-, or lidocaine-based anesthesia was followed by administration of antimicrobial solution, disinfection of the periorcular skin, eyelid, and lashes with 10% povidone iodine swabs, and instillation of a sterile lid speculum and 2 drops of 5% povidone iodine ophthalmic solution in the study eye. After intravitreal injection, finger-counting testing was performed to confirm central retinal artery perfusion.

### End Points and Statistical Analysis

The primary end point for the fixed-dose regimen was the mean change in baseline VA at the first study visit after the 3 monthly doses of 2.0 mg intravitreal ranibizumab. Secondary end points included the percentage of patients who experienced a loss or gain of  $\geq 15$  letters from baseline in ETDRS BCVA, the mean change in central retinal thickness over time, and the incidence and severity of ocular and nonocular adverse events. Statistical comparisons were performed with Student *t* tests, paired Student *t* tests, chi-square, and McNemar's test using SAS 9.1.3 (SAS Inc., Cary, NC) where appropriate. The fixed-dosed regimen primary and secondary end point study results are reported.

### Results

Eighty-seven patients had complete data through 3 months and were evaluated in this study. Three patients initially consented but withdrew before 3 months because of difficulties with transportation and other medical conditions precluding their ability to attend study visits. Baseline demographics and clinical findings were similar between patients randomized to cohorts A and B. There is no statistically significant difference in any category listed in Tables 1 and 2. Of the patients included, 42 were men and 45 were women (all Caucasian). Patients had a mean age of 76 years and received an average of 24 prior intravitreal anti-VEGF injections. Before enrollment, all patients had been treated with "strict CATT" OCT and clinical examination retreatment criteria guided by SD volume scans at every visit with a monthly or "treat and

Table 1. Patient Demographics at Screening Visit

	Cohort A	Cohort B	Total
Total no. of patients	45	42	87
Sex (male/female)	21/24	21/21	42/45
Age, yrs	76	77	76
Total previous no. of injections	25	23	24
Time elapsed since most recent injection (days)	36	36	36
VA (ETDRS letters)	68.4	70.1	69.2
VA (Snellen equivalent)	20/43	20/40	20/41
SD-OCT central retinal thickness ( $\mu\text{m}$ )	445.5	397.2	422.2

ETDRS = Early Treatment Diabetic Retinopathy Study; SD-OCT = spectral-domain optical coherence tomography; VA = visual acuity.

Table 2. Visual Acuity and OCT Changes

Parameter	Mean	Range	Standard Deviation
Age at screening (yrs)	+76.1	(+53 to +93)	±7.8
Total prior anti-VEGF (injections)	+24.0	(+9 to +51)	±11.5
Injections 12 mos before screen	+10.6	(+9 to +12)	±1.1
Baseline VA (ETDRS letters)	+69.2	(+36 to +83)	±9.8
VA gain at wk 1	+2.5	(−6 to +15)	±3.8
VA gain at mo 1	+3.7	(−8 to +18)	±4.4
VA gain at mo 2	+3.9	(−10 to +16)	±4.9
VA gain at mo 3	+3.3	(−16 to +17)	±6.4
Baseline OCT thickness (μm)	+422.2	(+217 to +860)	±141.7
OCT reduction at wk 1 (μm)	−48.4	(−232 to +14)	±49.1
OCT reduction at mo 1 (μm)	−7.5	(−205 to +55)	±50.4
OCT reduction at mo 2 (μm)	−42.4	(−207 to +71)	±54.9
OCT reduction at mo 3 (μm)	−33.1	(−196 to +37)	±52.1

ETDRS = Early Treatment Diabetic Retinopathy Study; OCT = optical coherence tomography; VA = visual acuity; VEGF = vascular endothelial growth factor.

extend” paradigm. Despite a protocol-mandated 30-day “wash-out” before enrollment, the average patient had a median of 11 injections in the year before enrollment (mean, 10.4 injections). Some 28% of patients had received 12 injections in the year before enrollment (exactly every 28 days). The average time between injections in the year before enrollment was every 31 days. Some 79.3% of patients had received ranibizumab as their only previous anti-VEGF therapy, whereas 20.7% of patients had received both ranibizumab and bevacizumab. Of the patients who had received both anti-VEGF therapies, the mean number of previous ranibizumab injections was 13.9 and the mean number of previous bevacizumab injections was 7.8. A review of available OCT images from the year before enrollment revealed that 886 of 923 visits (96.3%) had evidence of fluid (subretinal fluid, serous pigment epithelial detachments, or intraretinal cysts) and 81.6% of patients had fluid on OCT at every monthly visit in the year before enrollment. The mean time between the previous injection and the screening/day 0 treatment visit was 36 days in both cohorts. At study initiation, there was no statistically significant difference between VA and mean central retinal thickness measured by Heidelberg Spectralis between cohorts; at baseline, the mean vision for the entire group was 69.2 letters (Snellen equivalent = 20/41) and central retinal thickness was 422 μm.

Mean VA gain (ETDRS) over baseline was +2.5 letters at day 7 (Snellen equivalent = 20/37), +3.7 letters at month 1 (20/35), +3.9 letters at month 2 (20/35), and +3.3 letters (20/36,  $P = 0.001$ ) at month 3 (Fig 1A). At 3 months, 5 patients (6%) gained ≥15 ETDRS letters and 1 patient (1%) lost ≥15 letters. Mean OCT central subfield thickness improvement from baseline was −48.4 μm at day 7, −37.5 μm at month 1, −42.4 μm at month 2, and −33.1 μm ( $P = 0.01$ ) at month 3 (Fig 1B). Image-tracked Heidelberg change graphs revealed retinal thickness reductions at day 7 in almost every patient (Fig 2A, green on the graph represents negative change in retinal thickness and red represents increased thickness). This anatomic improvement was evident (al-

though slightly diminished) in most patients at months 1, 2, and 3 (Fig 2B–D).

Qualitative OCT analysis also showed that there was a resolution of intraretinal cysts or subretinal fluid in some patients (Fig 3). At baseline, 53.5% (46/86) and 83.7% (72/86) of patients had intraretinal cysts and subretinal fluid identified on OCT, respectively. By the 3-month timepoint, these percentages decreased to 50.0% (43/86) ( $P = 0.25$ ) and 69.8% (60/86) ( $P = 0.0005$ ), respectively. The relative risk from the start of the study to the 3-month end point was 0.93 (confidence interval, 0.70–1.25) for presence of cysts and 0.83 (confidence interval, 0.70–0.98) for subretinal fluid. There was only minimal resolution of subpigment epithelial fluid that could be identified.

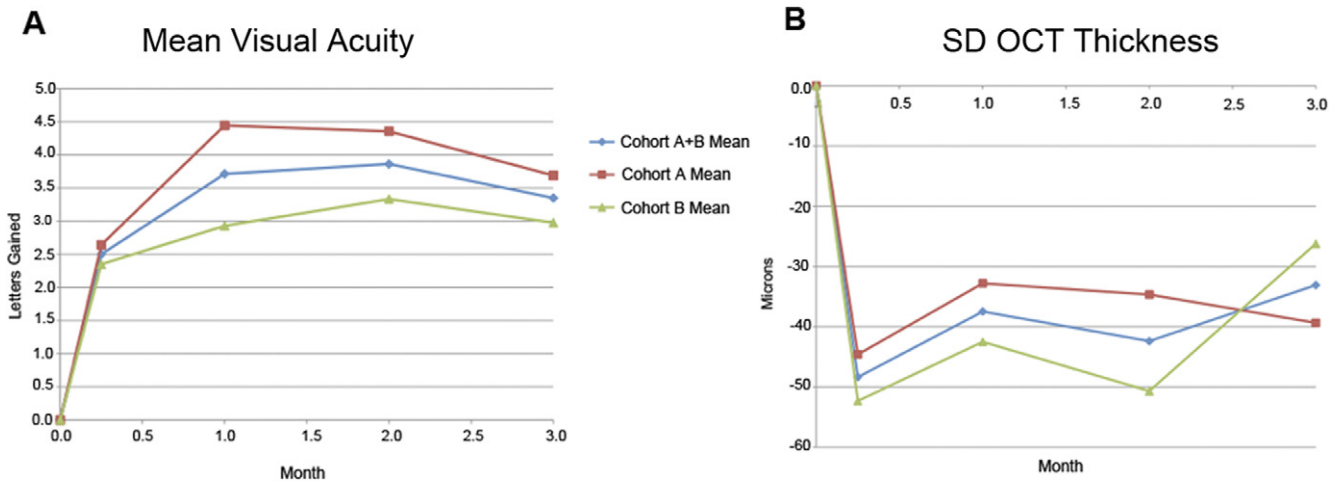
A significant ocular adverse event was observed in 1 patient who had an extensive subretinal hemorrhage (with a resultant 3-line decrease in BCVA). There were no other significant or unexpected ocular or systemic safety issues (Table 3). Specifically, there were no incidences of endophthalmitis, uncontrolled hypertension, or arterial thromboembolic events (myocardial infarction or cerebrovascular accident).

## Discussion

A higher intravitreal dose (2.0 mg ranibizumab) resulted in statistically significant improvements in VA and quantitative OCT measurements immediately after 3 consecutive monthly injections in a cohort of patients who were incomplete anatomic responders with conventional doses of ranibizumab and bevacizumab. Many patients also experienced qualitative improvements in anatomy as visualized by SD-OCT scans. This implies that the currently available dose of ranibizumab (0.5 mg) may not be at the peak of the dose-response curve and that a higher dose may result in better VA gains in patients with recalcitrant disease than the commercially available dose.

It is unknown why some eyes with neovascular AMD dry up anatomically with fewer intravitreal injections of anti-VEGF, whereas up to half have OCT findings of disease activity even with continuous monthly therapy.<sup>3</sup> It is possible that some patients may require a higher percentage of VEGF blockade to achieve disease quiescence or may have faster clearance of anti-VEGF drugs from their vitreous cavity. A higher concentration of anti-VEGF drug should theoretically address either hypothetical mechanism. In this study, at 3 months, 2.0 mg ranibizumab seemed to be more effective at eliminating subretinal fluid than residual intraretinal cysts. It is possible that some OCT fluid may be mediated by mechanisms other than VEGF, and the small intraretinal cysts seen in this study and the CATT may be the most resistant to anti-VEGF therapy.

The 0.5-mg commercially available ranibizumab dose was chosen for the phase II and III Food and Drug Administration registration trials because of inflammatory adverse events observed with the lyophilized test agent in doses >0.5 mg in the phase I trial<sup>6</sup>; Genentech, Inc., reformulated the 0.5-mg and 0.3-mg doses of ranibizumab into a liquid form for these trials. Another subsequent phase I study (Genentech Inc., study FVF2425g) reported that increasing doses up to 2.0 mg ranibizumab were well tolerated and demonstrated a beneficial clinical effect.<sup>7</sup> The current 2.0-mg/0.5-ml ranibizumab test dose used in the Super-dose



**Figure 1.** Change in mean visual acuity (VA) (ETDRS letters) (A) and central retinal thickness (SD-OCT thickness [ $\mu\text{m}$ ]) (B) in cohorts A and B over the 3-month fixed-dose end point. SD-OCT = spectral domain optical coherence tomography.

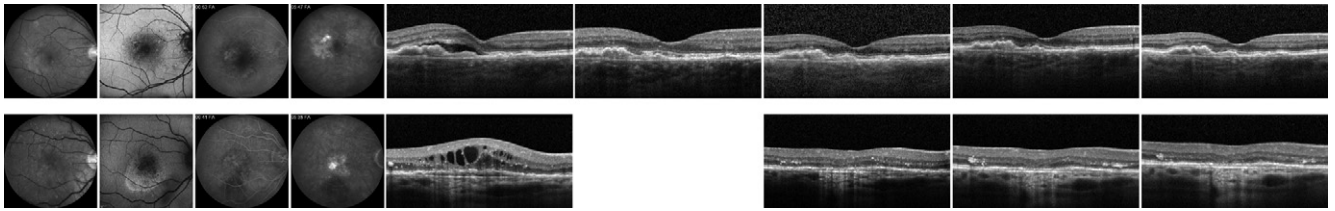
Anti-VEgf (SAVE) trial is a nonlyophilized investigational liquid formulation; there were no inflammatory episodes in any patient with this liquid formulation.

One patient (who had received 30 prior ranibizumab injections before the study) had a significant ocular adverse event during the course of the study. He had undergone

pneumatic displacement of subretinal hemorrhage 2 years before study entry. At screening, his ETDRS VA was 36 letters (20/191), and 22 days after the third 2.0-mg intravitreal ranibizumab injection, a submacular hemorrhage developed with a decrease in vision to 27 letters (20/289). It is unknown whether the higher dosage of ranibizumab played



**Figure 2.** Change maps for all patients after 1 week (A), 1 month (B), 2 months (C), and 3 months (D). Green indicates decrease in retinal thickening, and red indicates an increase in retinal thickening.



**Figure 3.** Case examples. OCT scans shown are from baseline, 1 week, 1 month, 2 months, and 3 months after treatment. Patient A (top) had received 15 prior anti-vascular endothelial growth factor (VEGF) injections (7 bevacizumab, 8 ranibizumab) but had persistent subretinal fluid. The visual acuity (VA) at screening was 78 letters (20/28) and improved to 82 letters (20/23) by the end of 3 months as the fluid resolved. Patient B (bottom) had 25 prior ranibizumab injections but had persistent intraretinal cysts. The VA at screening was 69 letters (20/42) and improved to 84 letters (20/21) by 3 months as the cysts resolved.

a role in this hemorrhage or whether this would have occurred with conventional dosing. No additional adverse events (systemic or ocular) were identified through month 3 in the other patients, but additional monitoring through month 24 will be necessary to assess whether the higher dose is accompanied by any change in the long-term side-effect profile.

Despite the chronic nature of disease activity in this patient population (and a mean of 24 prior anti-VEGF injections before enrollment), the mean VA at enrollment was good (20/41 Snellen equivalent). This demonstrates that chronic or persistent fluid can be associated with maintained VA gains with conventional monthly therapy. The further improvement of approximately 4 letters gained associated with decreased retinal thickness in these patients with 3 months of 2.0 mg ranibizumab is encouraging. The ongoing pHase III, double-masked, multicenter, randomized, Active treatment-controlled study of the efficacy and safety of 0.5 mg and 2.0 mg Ranibizumab administered monthly or on an as-needed Basis (PRN) in patients with subfoveal neOvasculaR age-related macular degeneration (HARBOR; NCT00891735, [Clinicaltrials.gov](http://Clinicaltrials.gov)) recently reported no difference in anatomic or VA outcomes in treatment-naïve patients randomized to 2.0 mg ranibizumab compared with 0.5 mg ranibizumab at the 1-year end point (Allen Ho, American Academy of Ophthalmology pre-academy late-breaking session, October 21, 2011, Orlando,

Florida). There are several possible explanations for the disparity in results between the HARBOR (in treatment-naïve patients) and the SAVE trial. The SAVE population (with its multiple years of prior anti-VEGF therapy) may have become relatively resistant to the 0.5-mg dose. Tachyphylaxis, where repeat administration of a drug leads to decreased therapeutic response, has been proposed with both bevacizumab and ranibizumab.<sup>8–11</sup> Possible mechanisms include VEGF receptor upregulation or increased production of other proangiogenic peptides (e.g., hypoxia-inducible factor and erythropoietin) secondary to lack of feedback loop inhibition from chronic VEGF suppression. An alternative explanation is that a small percentage of the population might have faster clearance of ranibizumab, leading to an effectively shorter half-life of the drug in the eye; this more rapid clearance may increase through development of a systemic immune response or other mechanisms. Although only 10% to 20% of treatment-naïve eyes with AMD seen in our clinic seem to be recalcitrant to standard ranibizumab, they represent a larger percentage of our clinic volume because almost all require indefinite monthly injections. The averaged data in the HARBOR study may have masked any significant benefit to this subpopulation, the members of which represent the largest treatment “burden” of our clinic.

In conclusion, further analysis of the anatomic data in the HARBOR study may provide insight into whether the 2.0-mg ranibizumab dose is helpful for any particular subset of treatment-naïve patients. If not, it is likely that the benefits observed with 2.0-mg dosing in the SAVE trial are secondary to relative resistance acquired with chronic anti-VEGF suppression. Continued follow-up of the SAVE cohort through 24 months will be necessary to determine whether the gains seen with 3 monthly injections can be sustained. Additional pharmacokinetic analyses are planned to assess whether this cohort has increased ranibizumab clearance from the vitreous cavity.

**Acknowledgments.** The authors thank Michael Y. Lin, MD, MPH, for assistance with statistical analysis.

## References

1. Brown DM, Kaiser PK, Michels M, et al, Anchor Study Group. Ranibizumab versus verteporfin for neovascular age-related macular degeneration. *N Engl J Med* 2006;355:1432–44.

Table 3. Ocular and Systemic Adverse Events

	Cohort A	Cohort B	Total
Subretinal hemorrhage	1	1	2
Intraretinal hemorrhage	1	0	1
Epiretinal membrane	1	0	1
Posterior vitreous detachment	0	1	1
Elevated IOP ( $\geq 25$ mm Hg)	0	1	1
Intraocular inflammation	0	0	0
Endophthalmitis	0	0	0
Pneumonia	0	1	1
Atrial fibrillation	0	1	1
Chest pain	1	0	1
Severe urinary tract infection	1	0	1
Uncontrolled hypertension	0	0	0
Myocardial infarction	0	0	0
Cardiovascular accident	0	0	0

IOP = intraocular pressure.

2. Rosenfeld PJ, Brown DM, Heier JS, et al. MARINA Study Group. Ranibizumab for neovascular age-related macular degeneration. *N Engl J Med* 2006;355:1419–31.
3. CATT Research Group, Martin DF, Maguire MG, Ying GS, et al. Ranibizumab and bevacizumab for neovascular age-related macular degeneration. *N Engl J Med* 2011;364:1897–908.
4. Gregori NZ, Feuer W, Rosenfeld PJ. Novel method for analyzing Snellen visual acuity measurements. *Retina* 2010;30:1046–50.
5. Brown DM, Regillo CD. Anti-VEGF agents in the treatment of neovascular age-related macular degeneration: applying clinical trial results to the treatment of everyday patients. *Am J Ophthalmol* 2007;144:627–37.
6. Rosenfeld PJ, Schwartz SD, Blumenkranz MS, et al. Maximum tolerated dose of a humanized anti-vascular endothelial growth factor antibody fragment for treating neovascular age-related macular degeneration. *Ophthalmology* 2005;112:1048–53.
7. Rosenfeld PJ, Heier JS, Hantsbarger G, Shams N. Tolerability and efficacy of multiple escalating doses of ranibizumab (Lucentis) for neovascular age-related macular degeneration. *Ophthalmology* 2006;113:623–32.
8. Keane PA, Liakopoulos S, Chang KT, et al. Comparison of the optical coherence tomographic features of choroidal neovascular membranes in pathological myopia versus age-related macular degeneration, using quantitative subanalysis. *Br J Ophthalmol* 2008;92:1081–5.
9. Schaal S, Kaplan HJ, Tezel TH. Is there tachyphylaxis to intravitreal anti-vascular endothelial growth factor pharmacotherapy in age-related macular degeneration? *Ophthalmology* 2008;115:2199–205.
10. Gasperini JL, Fawzi AA, Khondkaryan A, et al. Bevacizumab and ranibizumab tachyphylaxis in the treatment of choroidal neovascularisation. *Br J Ophthalmol* 2012;96:14–20.
11. Eghoj MS, Sorensen TL. Tachyphylaxis during treatment of exudative age-related macular degeneration with ranibizumab. *Br J Ophthalmol* 2012;96:21–3.

## Footnotes and Financial Disclosures

---

Originally received: February 2, 2012.

Final revision: August 1, 2012.

Accepted: August 3, 2012.

Available online: November 3, 2012. Manuscript no. 2012-156.

Retina Consultants of Houston, The Methodist Hospital, Houston, Texas.

Financial Disclosure(s):

The author(s) have no proprietary or commercial interest in any materials discussed in this article.

Funding: Research grant from Genentech. The funding organization had no role in the design or conduct of this research.

Preliminary data from this study were presented at: Association for Research in Vision and Ophthalmology, May 1–5, 2011, Fort Lauderdale, Florida.

Correspondence:

David M. Brown, MD, 6560 Fannin Street, Suite 750, Houston, TX 77030.  
E-mail: dmbmd@houstonretina.com.